



## PATIENT

Sadie Ramirez

## SPECIES

Canine

## BREED

Terrier Mix

## SEX

FS

## AGE

11yr

## WEIGHT

15lb

## INTERPRETED BY

R. McKenzie Daniel,  
DVM, DABVP  
(Canine and Feline)

## IMAGING PERFORMED BY

Michael Schacher

## HOSPITAL NAME

Emergency  
Veterinarians of Idaho

## REFERRING VET

Michael Schacher

## INVOICE

24624

## DATE

04/27/2026

## PRESENTING CLINICAL SIGNS

history of diabetes, 1 day history of anorexia, vomiting, and diarrhea

Abnormal PE/Chem/CBC/UA Results: ALT moderately elevated, ALP moderately elevated, survey x-rays revealed decreased serosal detail and possible cranial abdominal mass

## ULTRASONOGRAPHIC EXAMINATION OF THE ABDOMEN

### *Urinary System*

The urinary bladder was mildly distended in size with normal tone. The trigone, cystourethral junction, and visible pelvic urethra to a depth of 3 cm exhibited normal thickness and tone. Anechoic urine was present in the lumen with moderate non-dependent particulate sediment. The ureteral papillae were normal. The ureters were not visible which is normal. No evidence of inflammatory or neoplastic changes was noted.

Normal size and margination were present in the kidneys. A normal 1:3 cortex / medulla ratio was maintained. The medulla and cortices were uniform in texture with some increased echogenicity and mild to moderate loss of corticomedullary symmetry and definition expected for the age of the patient. No evidence of pelvic dilation was present. The left kidney measured 4.5 cm in length. The right kidney measured 5.2 cm in length.

The area of the aortic trifurcation was free of pathology.

### *Adrenal Glands*

The left adrenal gland was indistinctly visualized subjectively measuring 0.52 cm in width. The right adrenal gland was uniform in size and contour with a uniformly hypoechoic parenchyma. The right adrenal gland measured 0.53 cm width at the caudal pole.

### *Spleen*

The spleen was normal to mildly subnormal in size suggestive of mild volume contraction with symmetrical contour and mild parenchyma heterogeneity exhibiting pinpoint to focal hyperechoic parenchyma foci. No visualized masses or nodules were present.

### *Liver/Gallbladder*

The liver presented enlarged in size. The parenchyma of the liver was subjectively normal in echogenicity compared to the spleen and renal cortices. The liver parenchyma was uniform with a mildly coarse echotexture. The capsule of the liver was symmetrically rounded to mildly swollen in margination. An indistinctly marginated to irregular non-homogenous nodular possibly cystic intraparenchymal mass lesion was present in the mid-ventral liver measuring 3.8 cm in diameter. The hepatic and portal vasculature were normal in appearance without signs of congestion.

The gallbladder was non-distended in size with mildly thickened to possible edematous gallbladder wall. The gallbladder contained mild non-organized bile debris. The common bile duct was not visualized without overt evidence of dilation or post hepatic obstructive criteria.

### *Gastrointestinal*



## PATIENT

Sadie Ramirez

## SPECIES

Canine

## BREED

Terrier Mix

## SEX

FS

## AGE

11yr

## WEIGHT

15lb

## INTERPRETED BY

R. McKenzie Daniel,  
DVM, DABVP  
(Canine and Feline)

## IMAGING PERFORMED BY

Michael Schacher

## HOSPITAL NAME

Emergency  
Veterinarians of Idaho

## REFERRING VET

Michael Schacher

## INVOICE

24624

## DATE

04/27/2026

The stomach presented mild thickened wall. Intact wall layering was maintained and distinct. The stomach contained a mild amount of anechoic fluid.

The intestinal walls demonstrated intact wall layering and maintained 1:3 muscularis / mucosa ratio. The mucosa exhibited mild decreased echogenicity with occasional mucosal speckling. A segmental to diffuse ileus pattern consisting of mild fluid accumulation in the intestinal lumen was present without obstruction or foreign material.

The visualized colon exhibited normal intact visible wall with primarily empty descending colon lumen containing gas and minor non-formed fecal matter consistent with patient history.

### **Pancreas**

The right pancreas was prominent in size with capsule asymmetry and heterogeneous remodeled parenchyma exhibiting discrete hypoechoic parenchymal striations.

### **Free Abdomen**

No visualized overt lymphadenopathy was present.

Generalized omental hyperechogenicity and mild volume echogenic peritoneal effusion.

## **ULTRASONOGRAPHIC FINDINGS**

### **Primary**

- Hepatopathy with lobar, ill-defined non-homogenous nodular possibly cystic mass lesion-diabetic, vacuolar or cholestatic inflammatory hepatopathy or potential combination, lobar ill-defined necrosis, atypical abscess, neoplastic mass lesion possible
- Possible chronic cholecystitis with non-organized mild bile debris
- Acute gastroenterocolopathy
- Prominent non-homogenous remodeled to suspect mild edematous pancreas
- Omental hyperechogenicity, mild volume echogenic peritoneal effusion / peritonitis
- Chronic renal changes with urine sediment
- Mild volume contracted non-homogenous focally hyperechoic spleen -subjective benign

## **INTERPRETATION OF THE FINDINGS & FURTHER RECOMMENDATIONS**

Assuming normal clotting status and using 25ga needle, hepatic parenchyma and mass lesion FNA cytology along with effusion analysis cytology +/- C/S is recommended for further assessment. The pancreas did not overtly suggest significant active or necrotizing pancreatitis with chronic active pancreatitis and mild edema favored.

Gastrointestinal support, empirical therapy for chronic active pancreatitis and non-specific peritonitis, pending additional diagnostics is recommended. A guarded prognosis is indicated.

A urine C/S on sterile urine sample given suspect inflammatory sediment or if glucosuria is recommended.

### **Colloids/Hetastarch**



**PATIENT**

Sadie Ramirez

10 to 20 mL per kilogram per hour and dogs  
10 to 15 mL per kilogram per hour cats  
(Can bolus first 1/3 of dose over 15 minutes)

**SPECIES**

Canine

**Plasma** 10 mL / kilogram IV over 4 hours  
**Buprenorphine** 0.02 mg/kg IV IM SC q4-6 hours **Or CRI Lidocaine** 30-50 ug/kg/min

**BREED**

Terrier Mix

**Dolasetron** for nausea: 0.6-1 mg/kg/day Iv or PO

**Famotidine** 1 mg/kg IV IM p.o. dc s.i.d. /b.i.d.

**Sucralfate** 0.5-1 g p.o. t.i.d. dogs, 0.5 g bid cats in slurry **Or Misoprostol** 1-5 ug/kg po tid

**Clindamycin** 10mg/kg IV p.o. bid

**Enrofloxacin** 10-15 mg/kg IV p.o. s.i.d. dogs, 5 mg/kg Iv po Sid cats

**Metronidazole** 10-20 mg/kg IV p.o. b.i.d.

**Dexamethasone** physiological 1 mg/kg to treat adrenal burnout if long standing sickness, shock dose 4-10 mg/kg.

**SEX**

FS

**AGE**

11yr

**WEIGHT**

15lb

**INTERPRETED BY**

R. McKenzie Daniel,  
DVM, DABVP  
(Canine and Feline)

**IMAGING PERFORMED BY**

Michael Schacher

**HOSPITAL NAME**

Emergency  
Veterinarians of Idaho

**REFERRING VET**

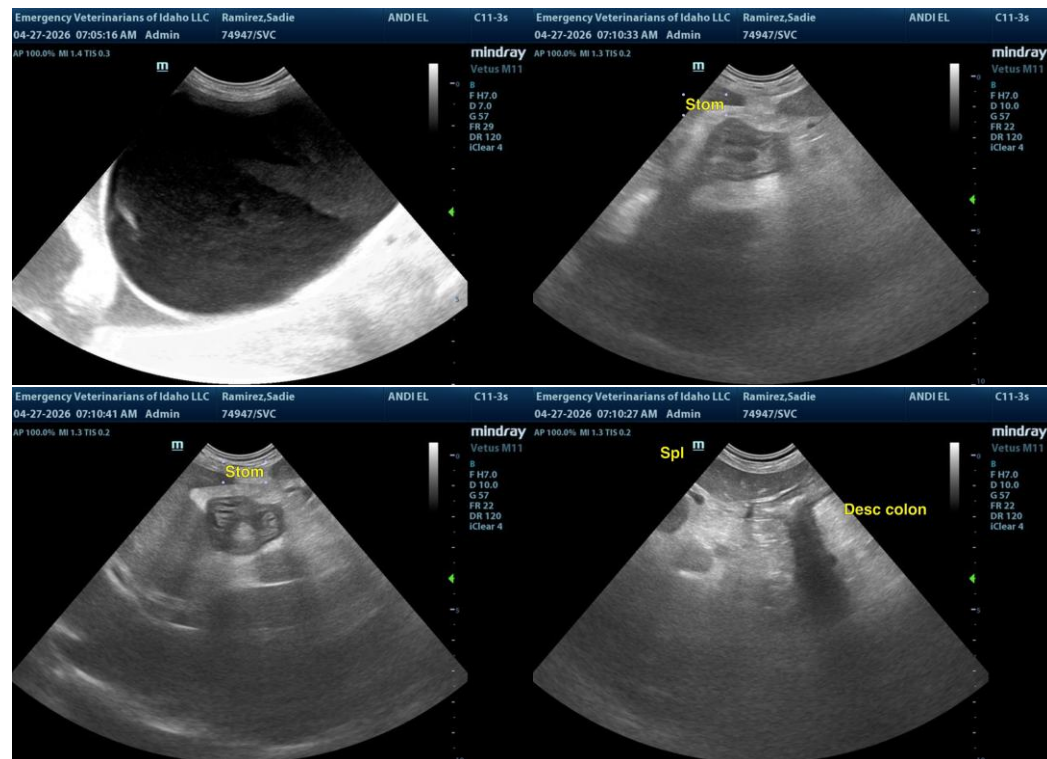
Michael Schacher

**INVOICE**

24624

**DATE**

04/27/2026





**PATIENT**

Sadie Ramirez

**SPECIES**

Canine

**BREED**

Terrier Mix

**SEX**

FS

**AGE**

11yr

**WEIGHT**

15lb

**INTERPRETED BY**

R. McKenzie Daniel,  
DVM, DABVP  
(Canine and Feline)

**IMAGING PERFORMED BY**

Michael Schacher

**HOSPITAL NAME**

Emergency Veterinarians of Idaho

**REFERRING VET**

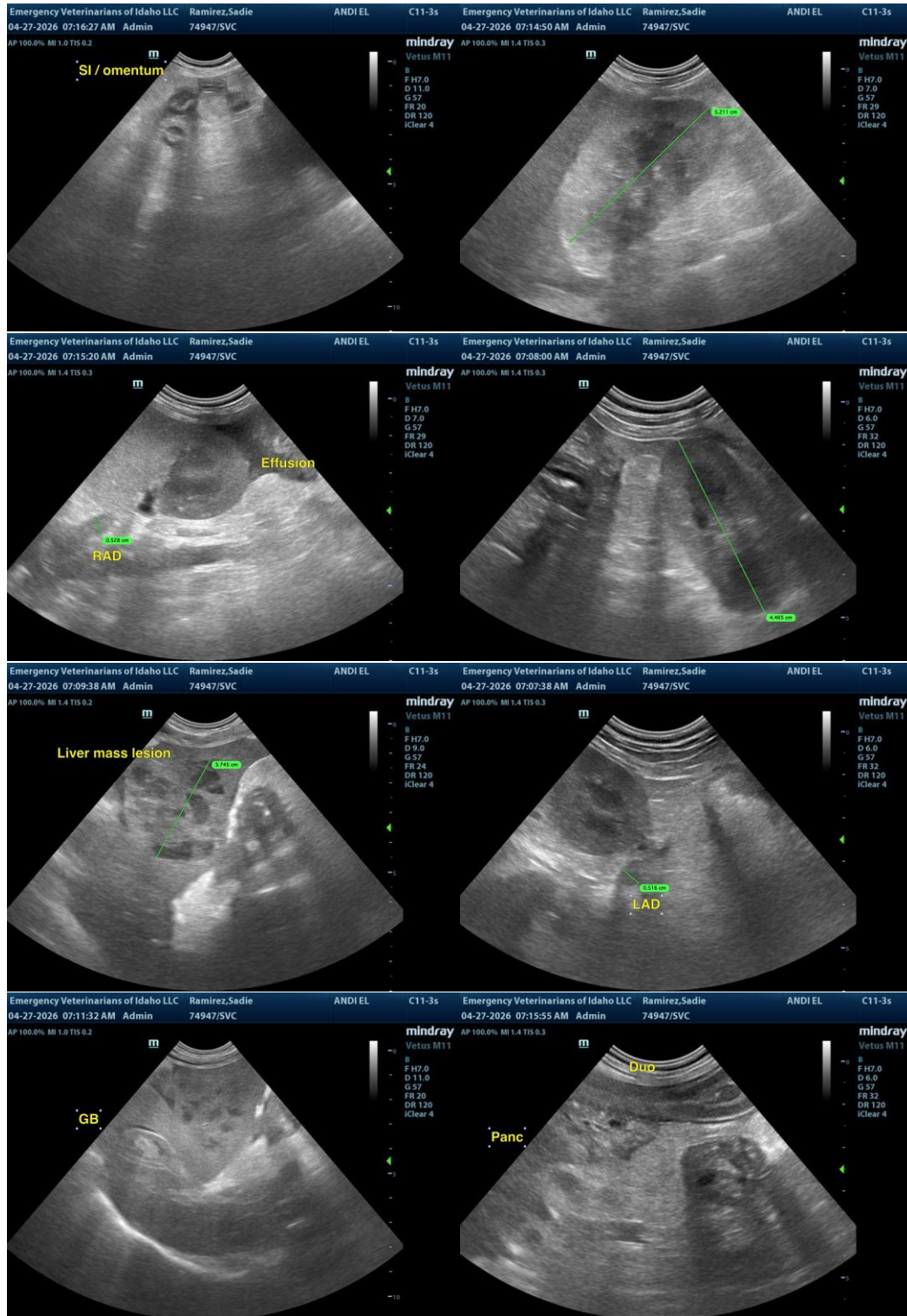
Michael Schacher

**INVOICE**

24624

**DATE**

04/27/2026





## PATIENT

Sadie Ramirez

The information and recommendations provided are based on the images presented by the referring veterinarian/sonographer. No evaluation can be communicated regarding pathology that was not visible in the image/video clips provided.

## SPECIES

Canine

Thank you for this referral. If the clinical or image interpretation does not parallel your findings or if I can be of any further assistance, please contact me.

## BREED

Terrier Mix

R. McKenzie Daniel, DVM, DABVP (Canine/Feline Practice)  
[info@sonopath.com](mailto:info@sonopath.com)

## SEX

FS

## AGE

11yr

## WEIGHT

15lb

## INTERPRETED BY

R. McKenzie Daniel,  
DVM, DABVP  
(Canine and Feline)

## IMAGING PERFORMED BY

Michael Schacher

## HOSPITAL NAME

Emergency  
Veterinarians of Idaho

## REFERRING VET

Michael Schacher

## INVOICE 24624

DATE  
04/27/2026